

# EYELIDS

## Lecture one

الدكتور  
مقداد فؤاد  
أستاذ مساعد

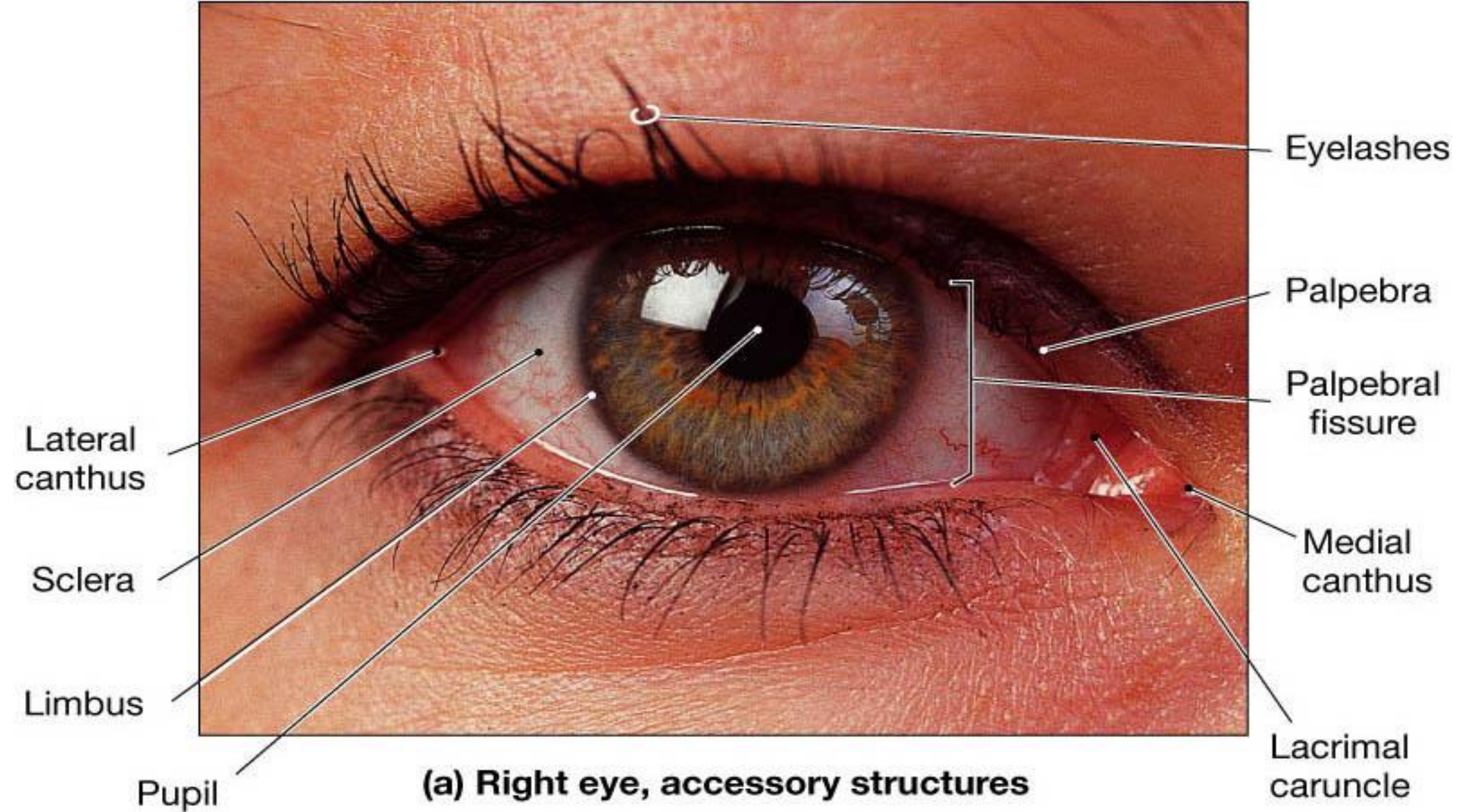


*kanash*

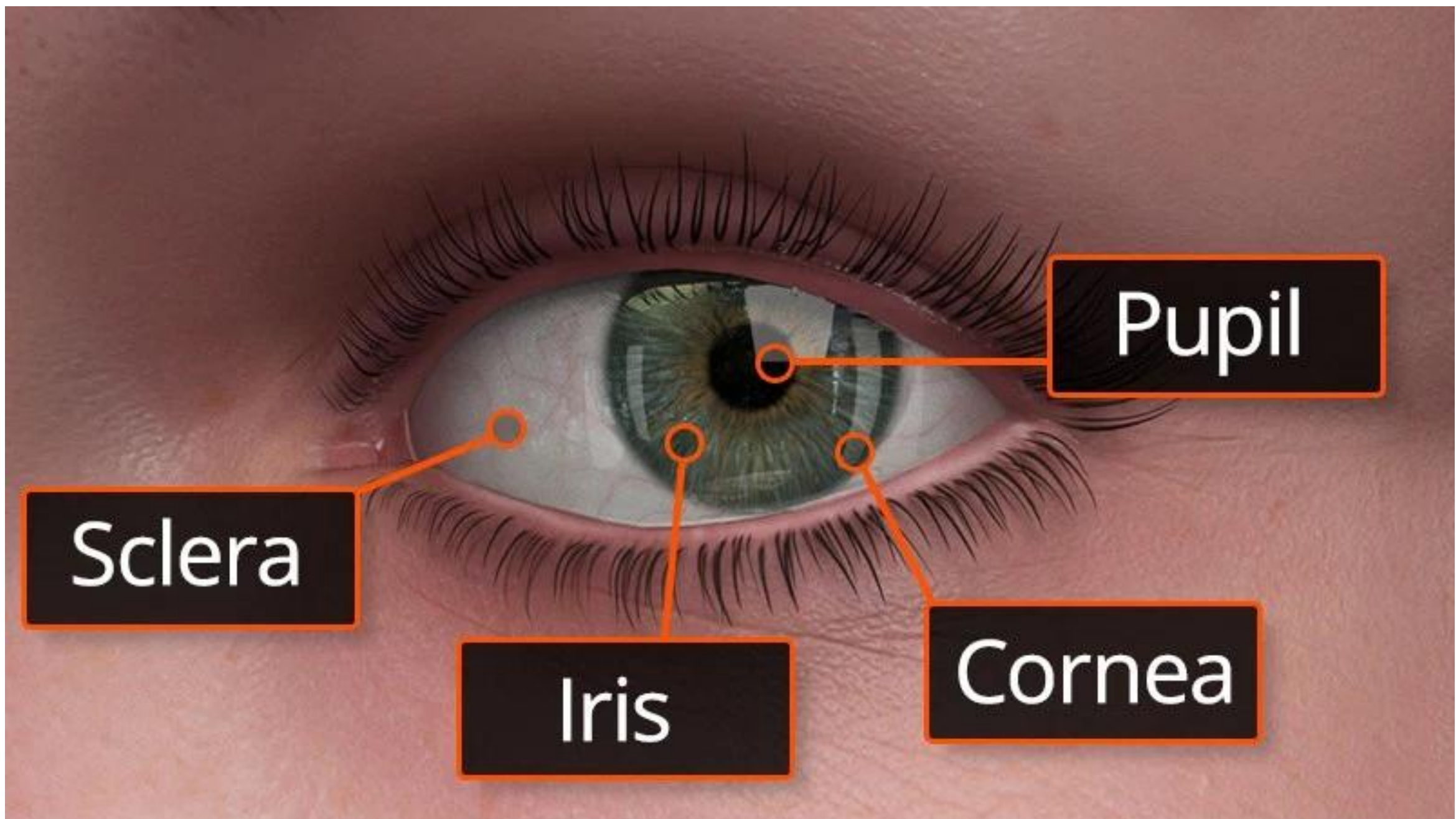
# Eyelids

- The eyelids protect the eye by **preventing contact** with foreign materials and by **preventing excessive drying** of the cornea and conjunctiva.
- The palpebral fissure must be wide enough to allow light to enter the pupil and should close sufficiently to provide protection and moisture to the globe.
- The lid contours and palpebral fissures should be symmetric to avoid cosmetic deformity.









Sclera

Iris

Pupil

Cornea

**Structure of the eyelids:** The eyelids consist of superficial and deep layers.

### + **Superficial layer:**

- Thin, well vascularized layer of **skin**.
- Sweat glands.
- Modified **sweat gland** and **sebaceous glands** (ciliary glands or **glands of Moll**) and **sebaceous glands** (**glands of Zeis**) in the vicinity of the eyelashes.
- Striated muscle fibers of the **orbicularis oculi muscle** that actively closes the eye (supplied by the facial nerve).

## **Deep layer:**

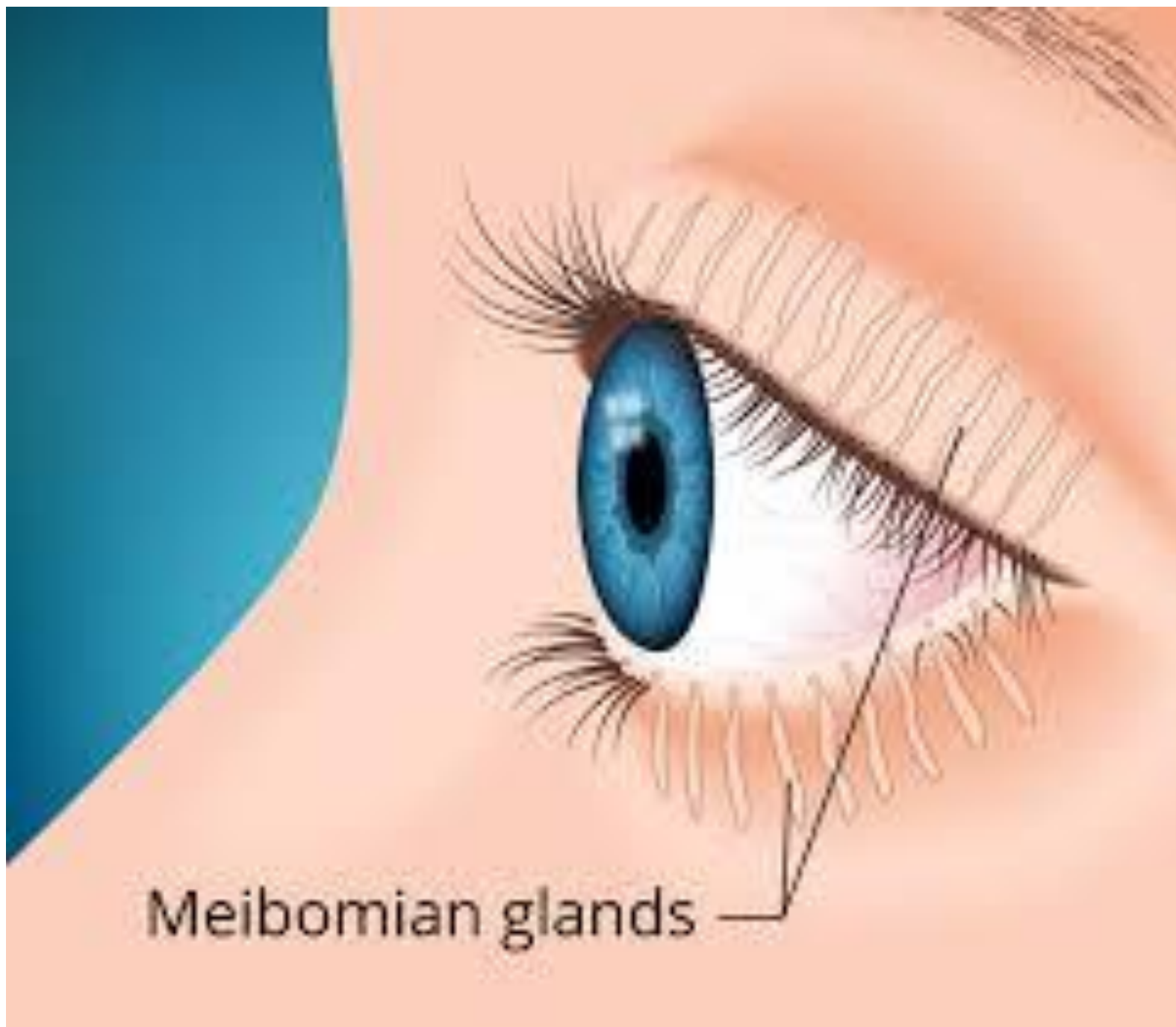- The **tarsal plate** gives the eyelid firmness and shape.
- **The upper lid elevators** (levator muscle, levator aponeurosis, and superior tarsal muscle {Müller muscle })
- **The lower lid retractors** (inferior rectus fascia and inferior tarsal muscle).
- The levator muscle is innervated by the third cranial nerve, whereas Müller muscle and the inferior tarsal muscle are innervated by sympathetic nerves.

–**The tarsal muscles** supplied by the sympathetic nervous system and regulates the width of the palpebral fissure. High sympathetic tone contracts the tarsal muscle and widens the palpebral fissure; low sympathetic tone relaxes the tarsal muscle and narrows the palpebral fissure.

– The **palpebral conjunctiva** is firmly attached to the tarsal plate. Every time the eye blinks, it acts like a wind shield wiper and uniformly distributes glandular secretions and tears over the conjunctiva and cornea.



- **Sebaceous glands (tarsal or meibomian glands)**, tubular structures which lubricate the margin of the eyelid.
- Their function is to prevent the escape of tear fluid past the margins of the eyelids.
- **The fibers of Riolan's** muscle at the inferior aspect of these sebaceous glands squeeze out the ducts of the tarsal glands every time the eye blinks.



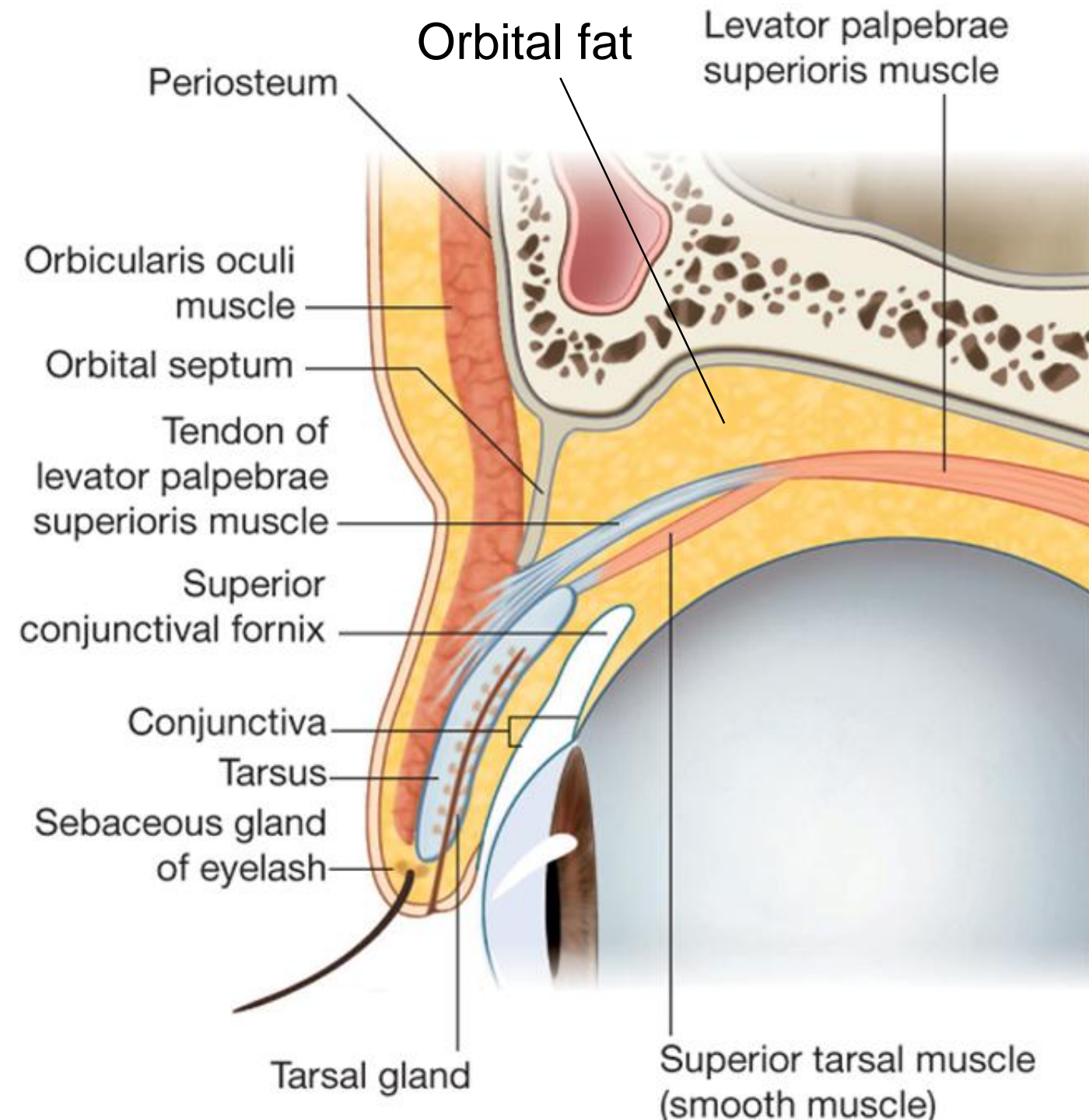
Meibomian glands

- The lids and palpebral fissures are maintained in a stable position by periosteal attachments provided by the medial and lateral canthal tendons.
- The palpebral fissure is closed by the orbicularis muscle, which is innervated by the **seventh cranial nerve**.

The **eyelashes** project from the anterior aspect of the margin of the eyelid. On the upper eyelid, approximately 150 eyelashes are arranged in three or four rows; on the lower eyelid there are about 75 in two rows.

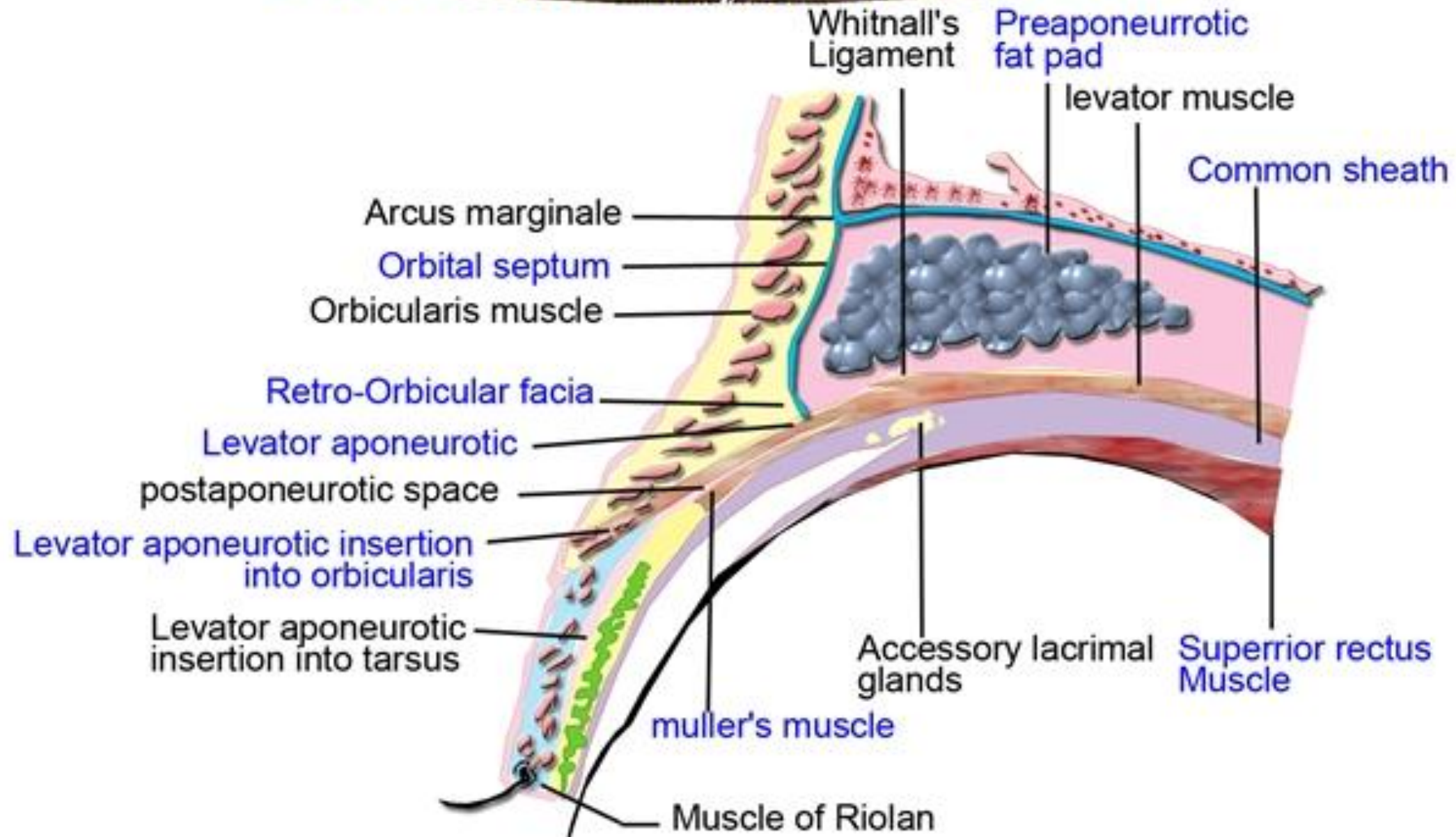
Like the **eyebrows**, the eyelashes help prevent dust and sweat from entering the eye. The **orbital septum** is located between the tarsal plate and the margin of the orbit. It is a membranous sheet of connective tissue attached to the margin of the orbit that retains the orbital fat.

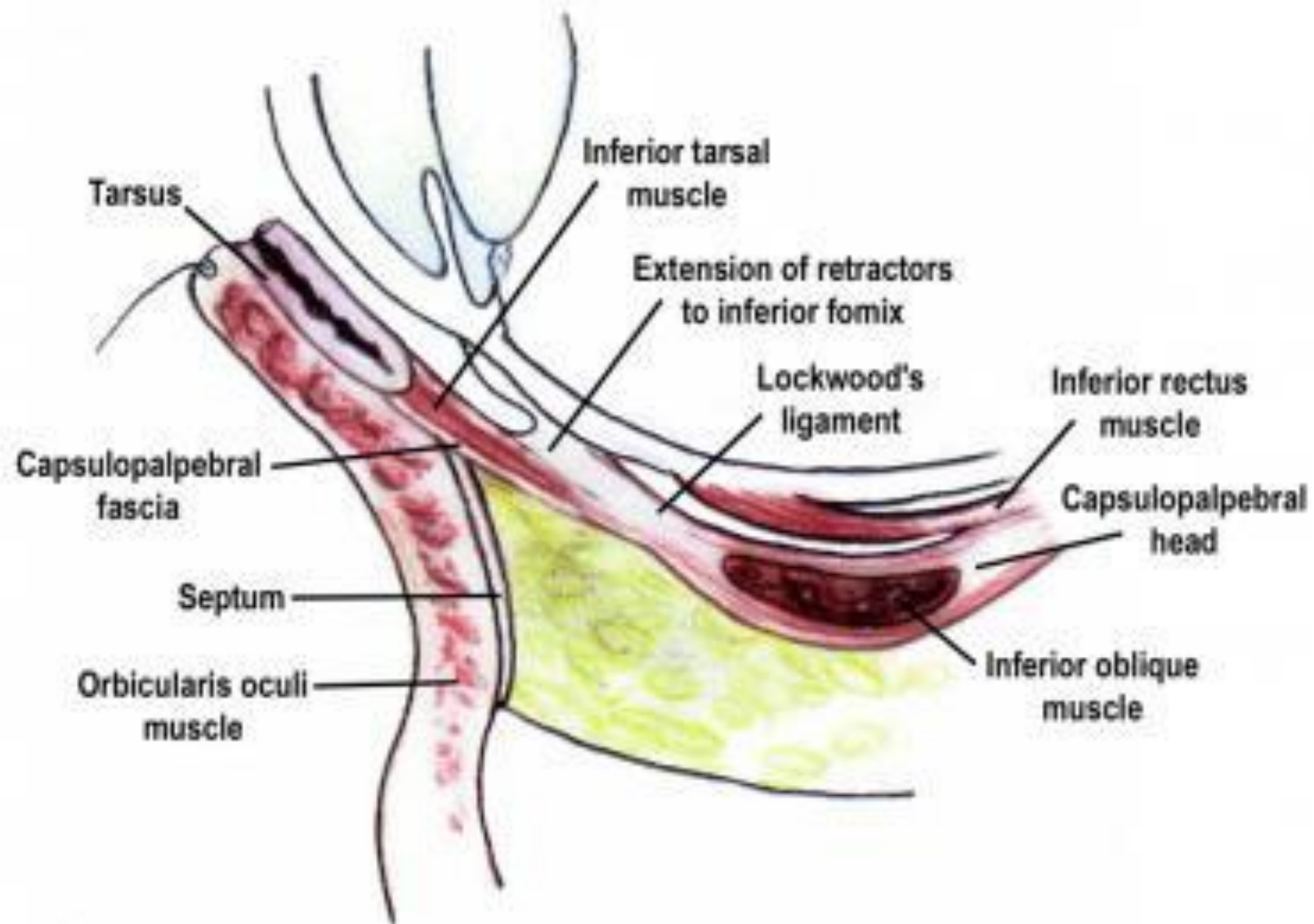




## Anatomy of the upper eyelid

# SECTION THROUGH THE UPPER EYELID

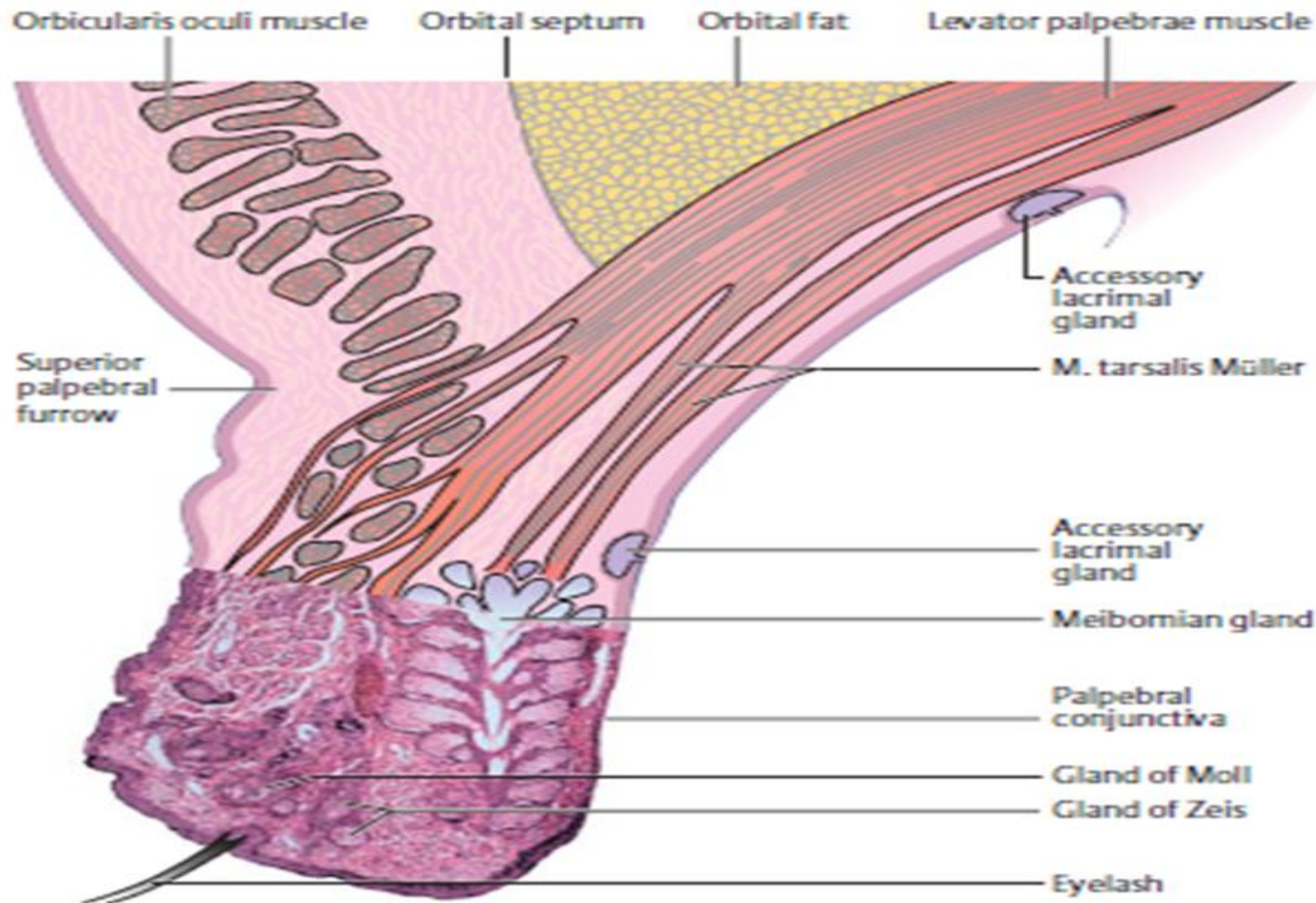




**Surgical anatomy of lower eyelid**



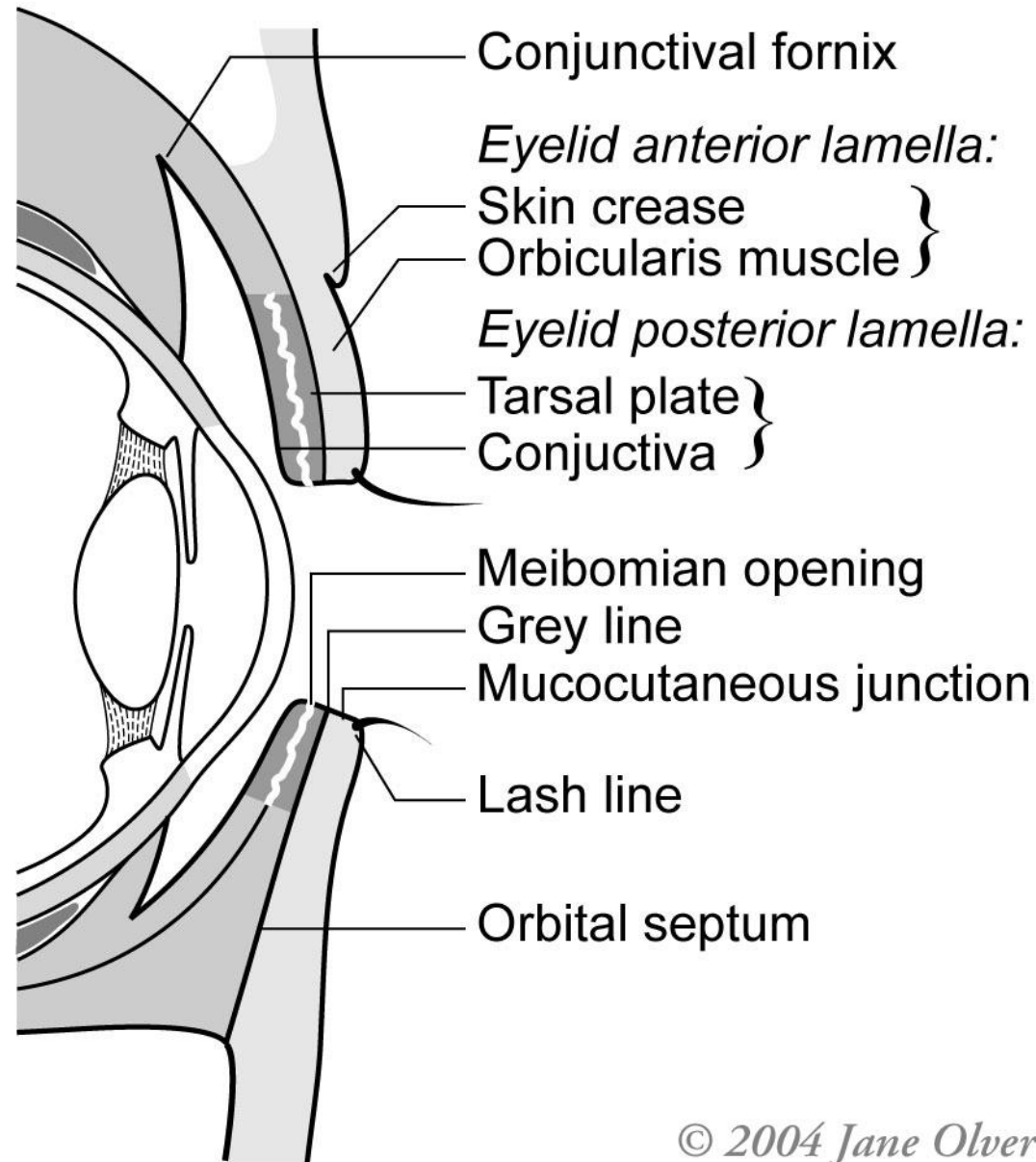
**Sagittal section through the upper eyelid.**

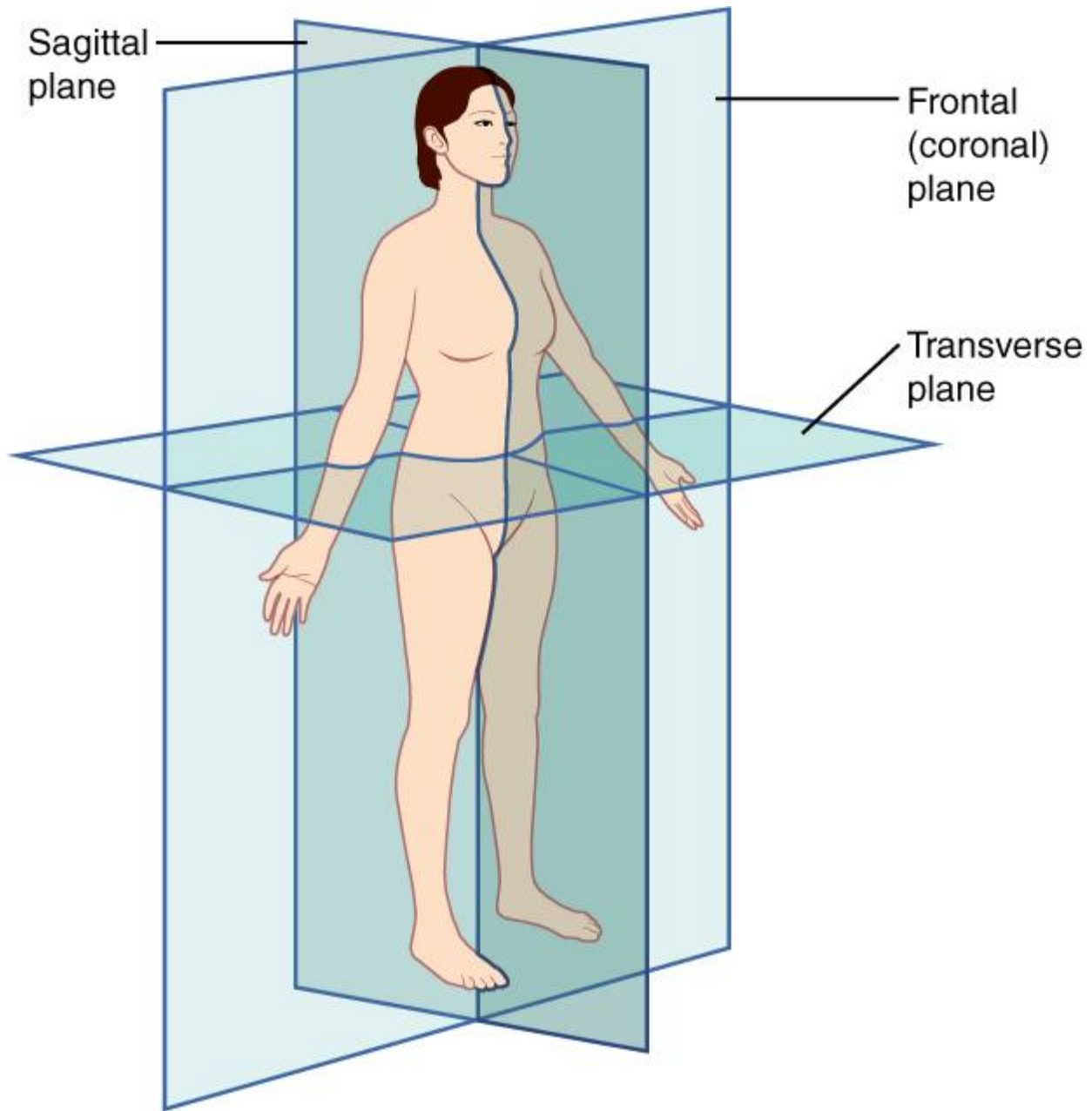


The superficial layer of the eyelid consists of the skin, glands of Moll and Zeis, and the orbicularis oculi and levator palpebrae muscles. The deep layer consists of the tarsal plate, tarsal muscle, palpebral conjunctiva, and meibomian glands.



# Eyelid Anatomy: Cross section lids



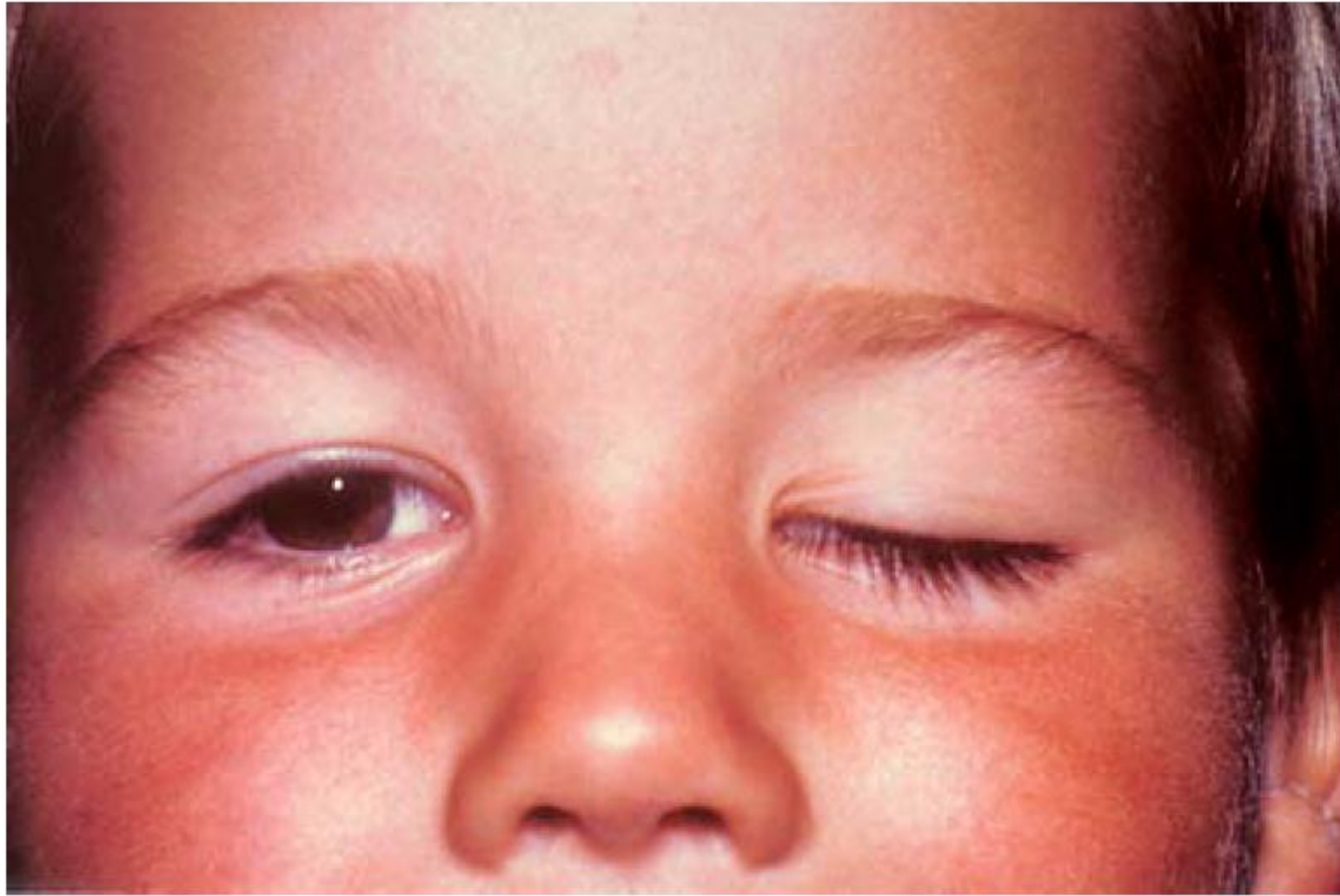

# Congenital and developmental eyelid anomalies

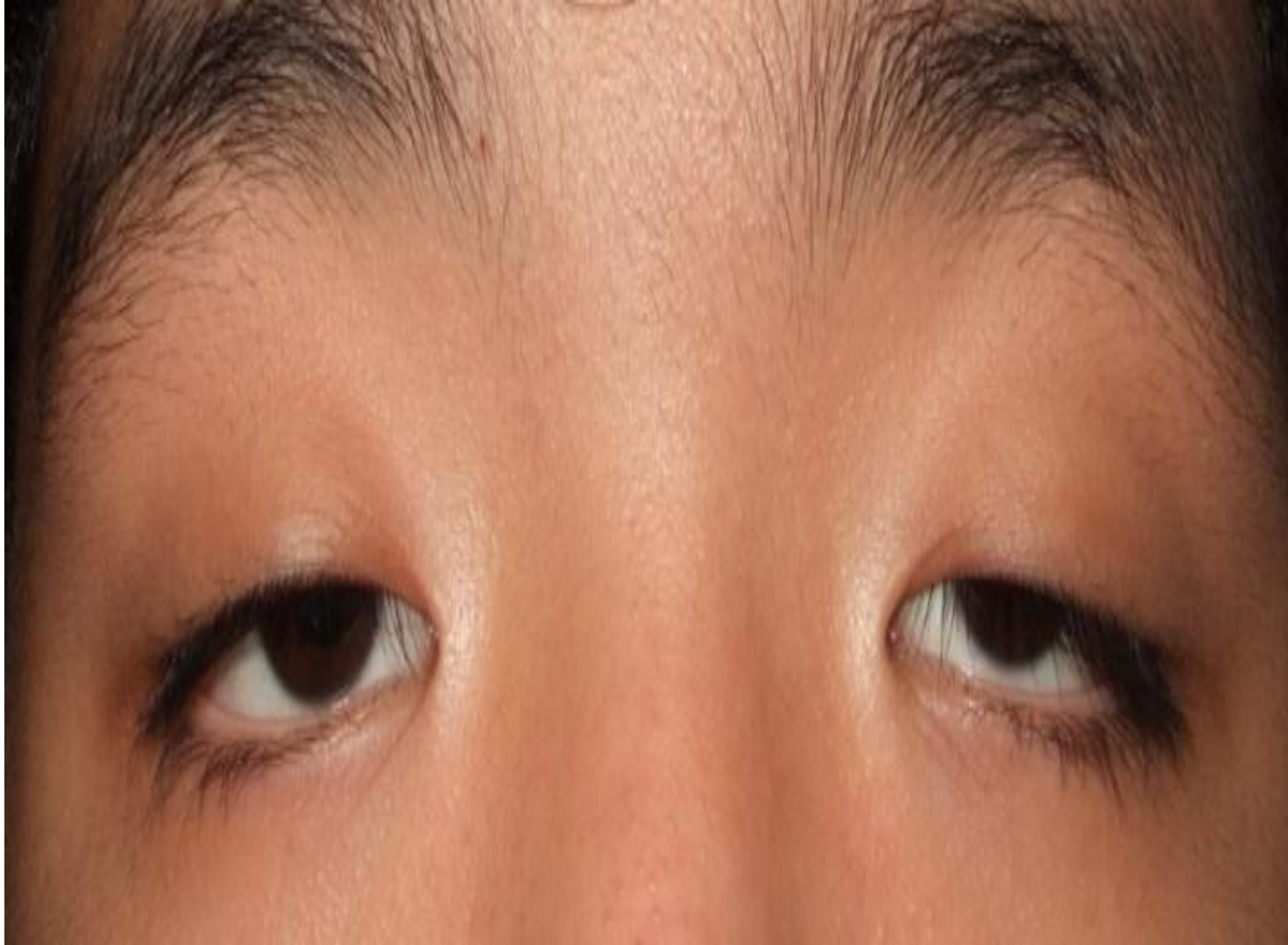## **Ptosis**

- It is paralysis of the levator palpebrae muscle with resulting drooping of one or both upper eyelids

**Congenital ptosis.**







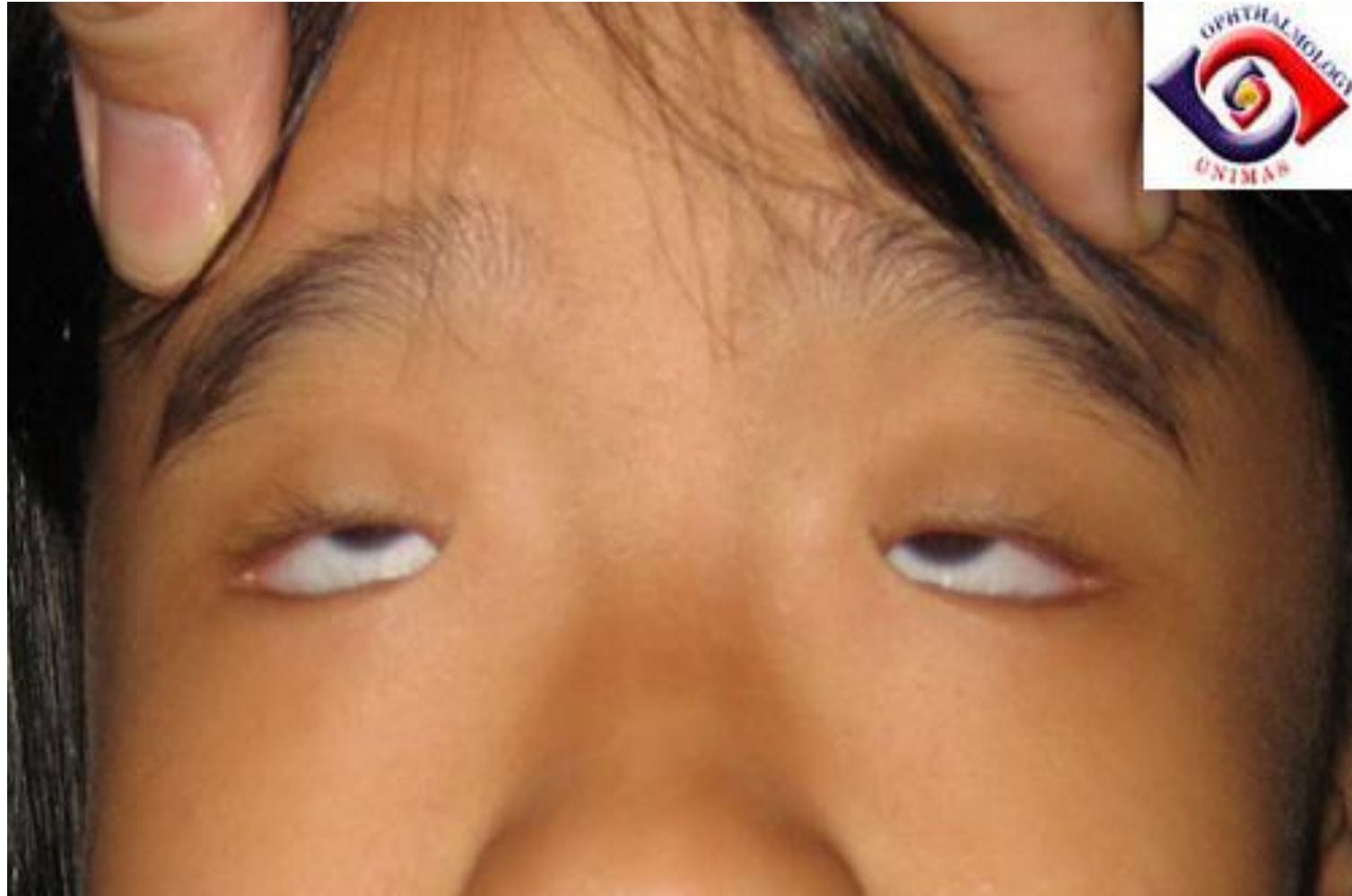# Congenital ptosis

- It is usually unilateral, although approximately one-fourth of the cases involve both upper eyelids. It may be associated with other abnormalities
- The disorder is usually hereditary and is primarily autosomal dominant.
- Most congenital ptosis is caused by *aplasia in the core of the oculomotor nerve (neurogenic)* that supplies the levator palpebrae muscle
- less frequently it is attributable to an *underdeveloped levator palpebrae muscle (myogenic)*

- Many cases of congenital ptosis are associated with other developmental abnormalities such as:
- **blepharophimosis** and **epicanthus inversus** (ptosis syndrome)
  - Marcus Gunn “jaw-winking” syndrome, in which the ptotic eyelid is elevated with movement of the mandible.
  - Extraocular muscle palsies, particularly those involving the superior rectus and inferior oblique muscles ipsilateral to the ptosis.

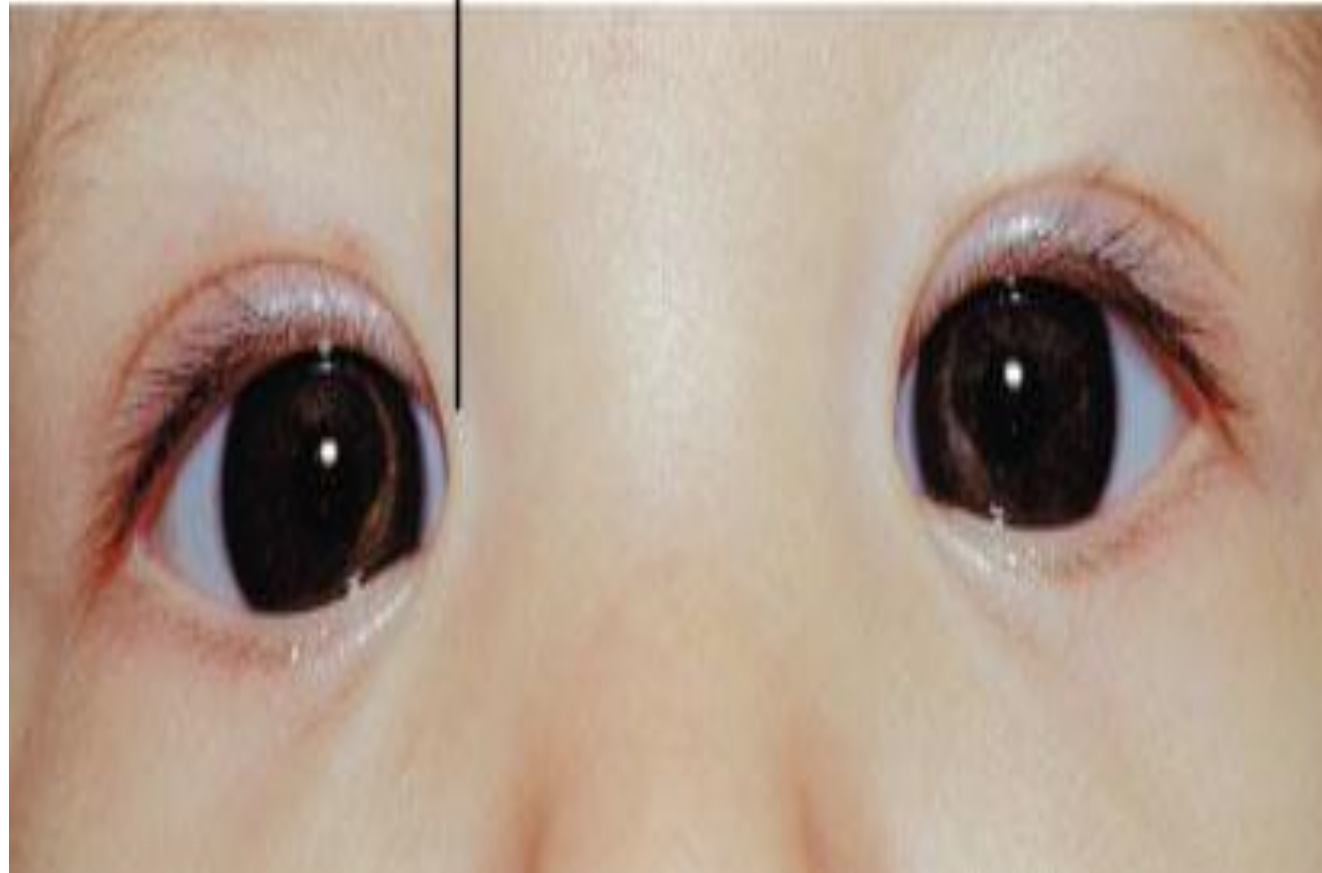
- **Blepharophimos** is a generalized narrowing of the palpebral fissure. This abnormality is frequently associated with congenital ptosis and epicanthus.
- **Epicanthus** is a semilunar fold of skin that crosses the medial canthus. Blepharophimosis and epicanthus should usually be repaired prior to surgical correction of ptosis.
- Treatment of congenital ptosis usually requires resection of part of the weak levator muscle and aponeurosis (surgical retraction), or suspension of the lids from the frontalis muscle (brow).





**Blepharophimos**

Epicanthus



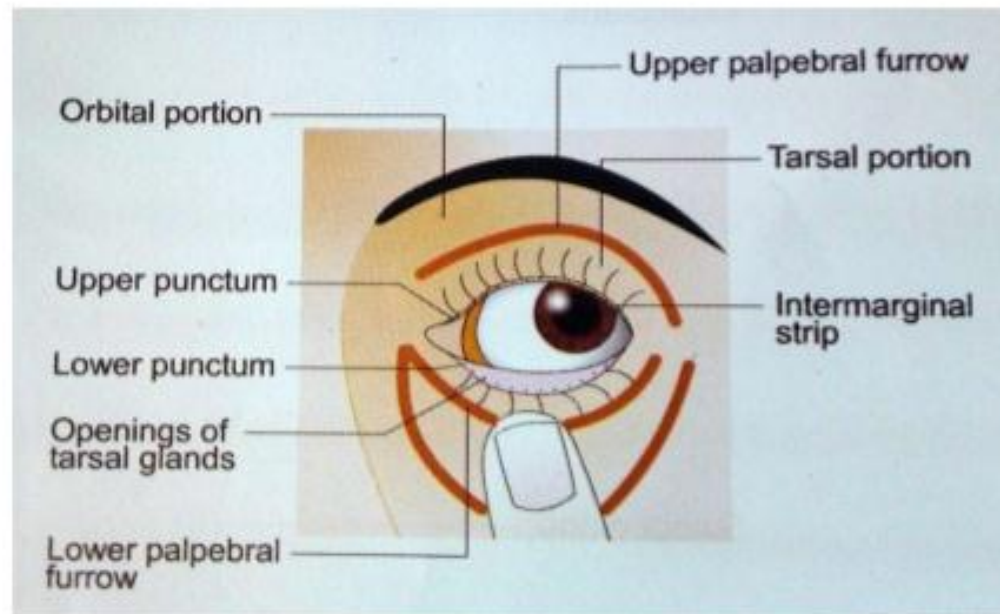
# Diagnostic considerations

## Congenital ptosis

- The affected eyelid in general is underdeveloped.
- The skin of the upper eyelid is smooth and thin;
- The superior palpebral furrow is absent or ill-defined.
- A typical symptom is “*lid lag*” in which the upper eyelid does not move when the patient glances down. *This important distinguishing symptom excludes acquired ptosis in differential diagnosis.*
- In about 3% of all cases, congenital ptosis is associated with epicanthal folds and blepharophimosis (*Ptosis syndrome*).

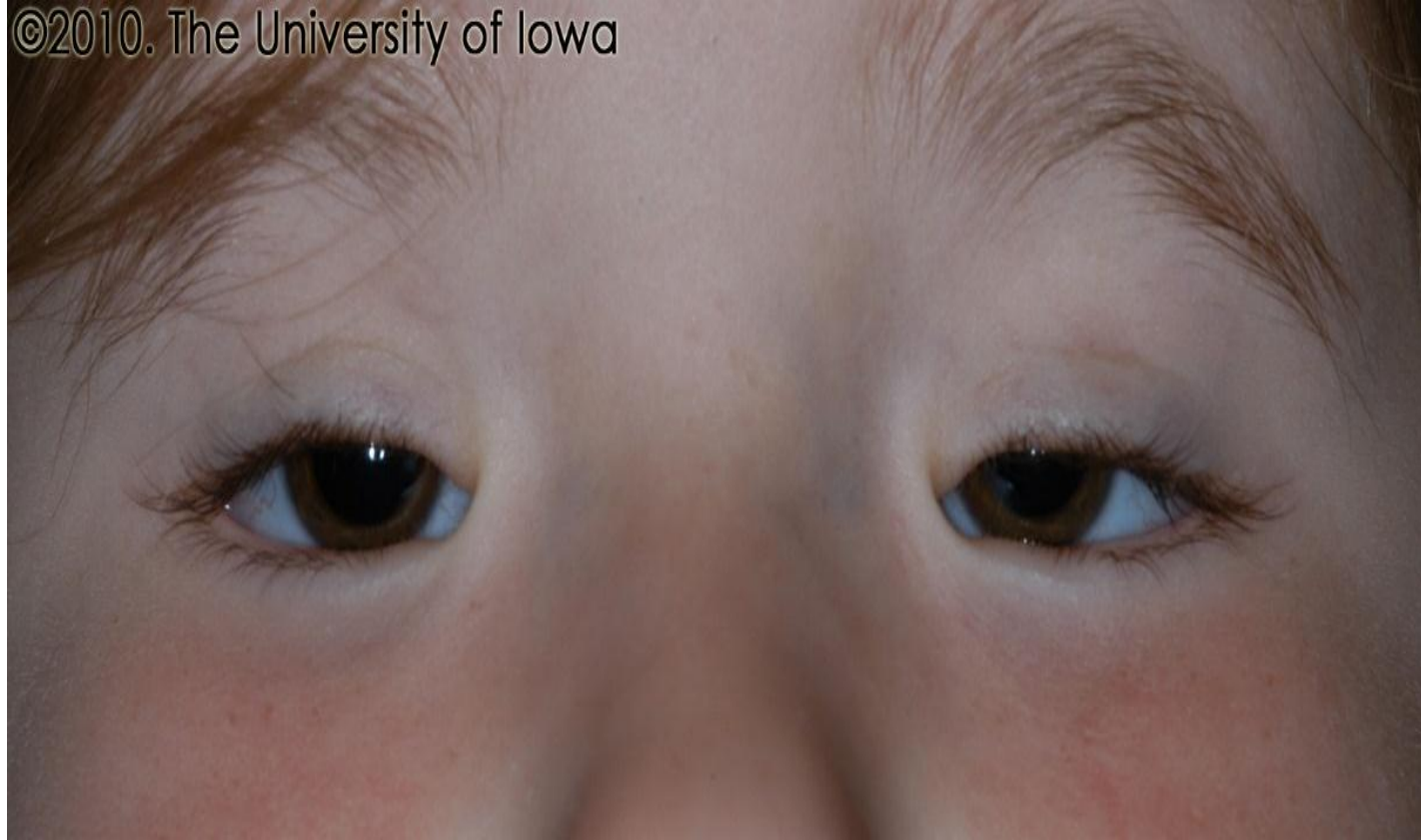## PARTS OF EYELIDS

- Each eyelid is divided by a horizontal furrow (sulcus) into an orbital and tarsal part.





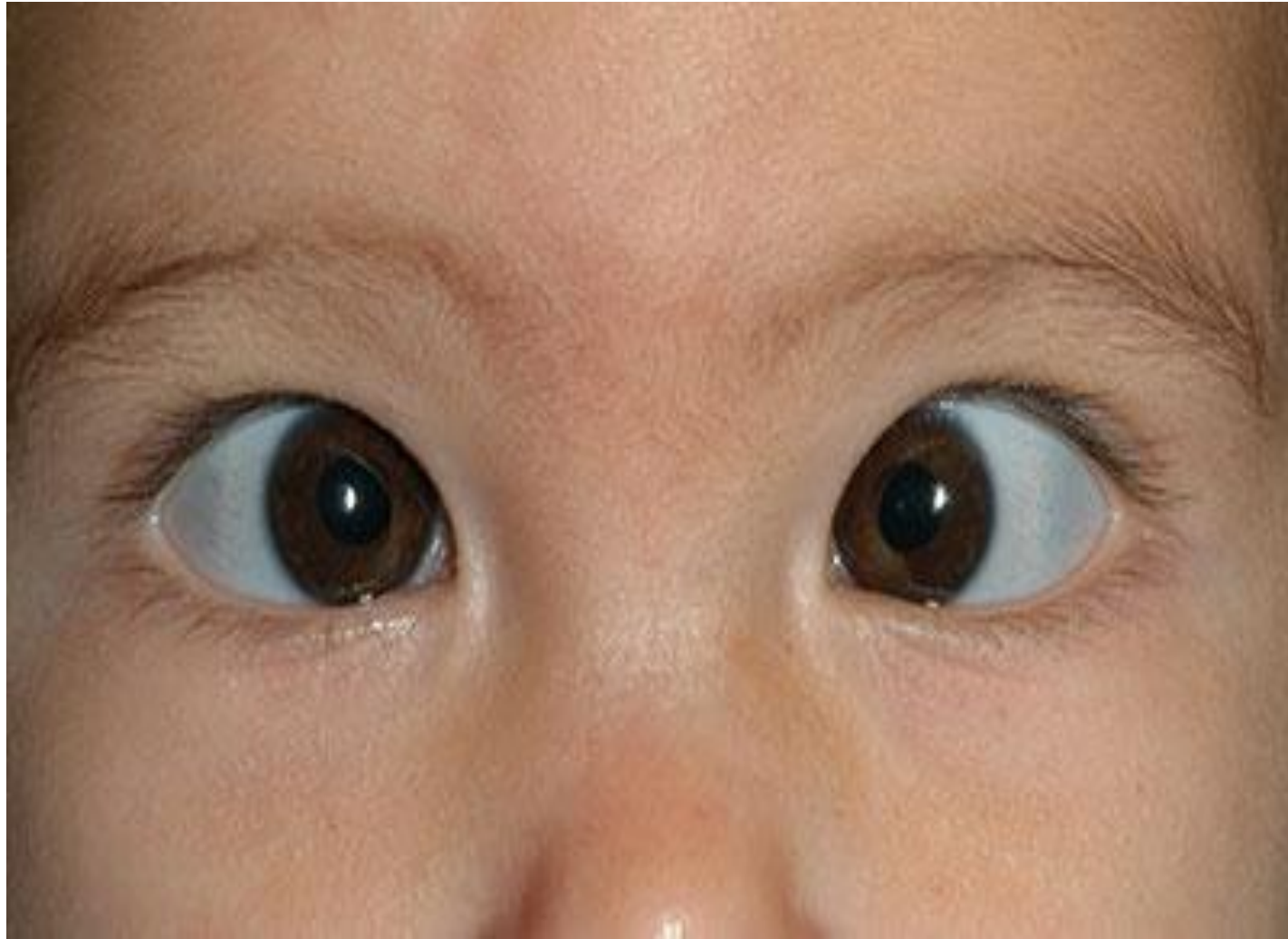©2010. The University of Iowa



**Ptosis syndrome (epicanthal folds + blepharophimosis)**

# Complications of Congenital ptosis

1. Presence of additional eyelid and ocular muscle disorders such as *strabismus*.
2. Congenital ptosis in which the upper eyelid droops over the center of the pupil always involves an increased risk of *amblyopia*.



**Strabismus**



***amblyopia (Lazy eye)***



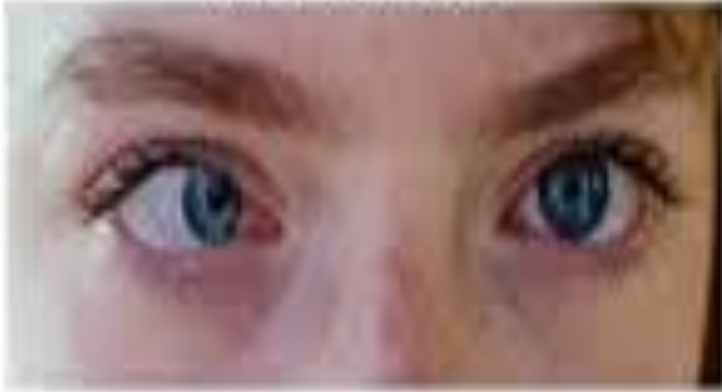**Strabismus** is a disorder in which both eyes do not line up in the same direction (misalignment), so they do not look at the same object at the same time. The condition is more commonly known as "**crossed eyes.**"

### **Types of strabismus:**

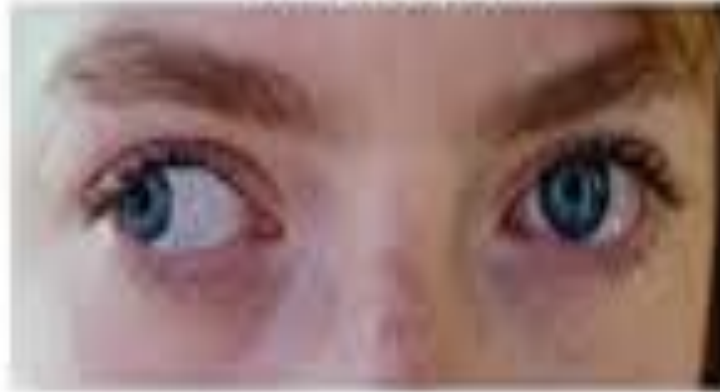- **Hypertropia** is a condition of misalignment of the eyes (strabismus), whereby the visual axis of one eye is higher than the fellow fixating eye.
- **Hypotropia** is a condition with the visual axis of one eye is lower than the fellow fixating eye.

- **Esotropia** is a form of strabismus, or “squint,” in which one or both eyes turns inward
- **Exotropia** is a form of strabismus where the eyes are deviated outward. It is the opposite of esotropia.

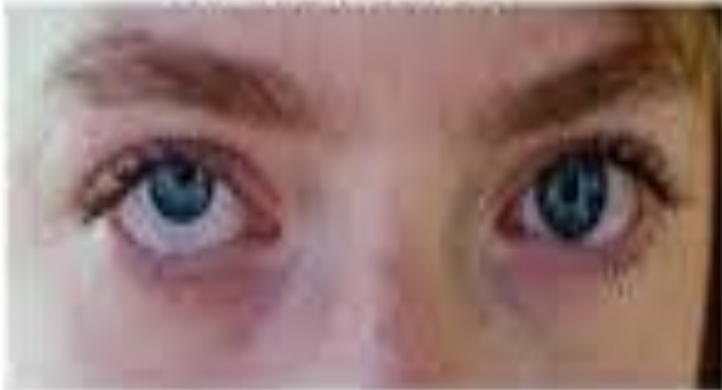**A. Esotropia**



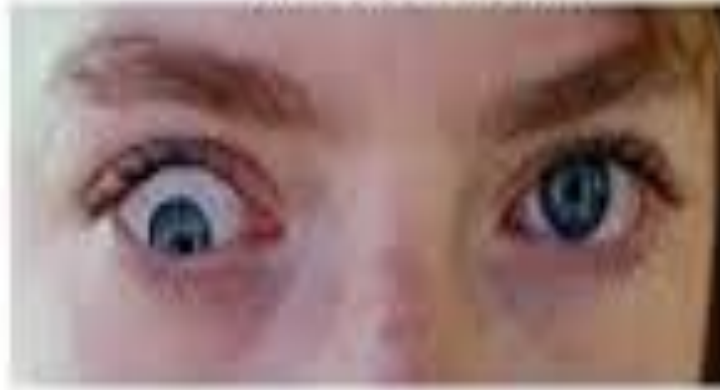**B. Exotropia**



**C. Hypertropia**



**D. Hypotropia**



# **Types of strabismus**

**Amblyopia**, or "**lazy eye**" is the most common cause of visual impairment in children. **It happens when an eye fails to work properly with the brain.** The eye may look normal, but the brain favors the other eye. It can be hard to diagnose amblyopia. It is often found during a routine vision exam.

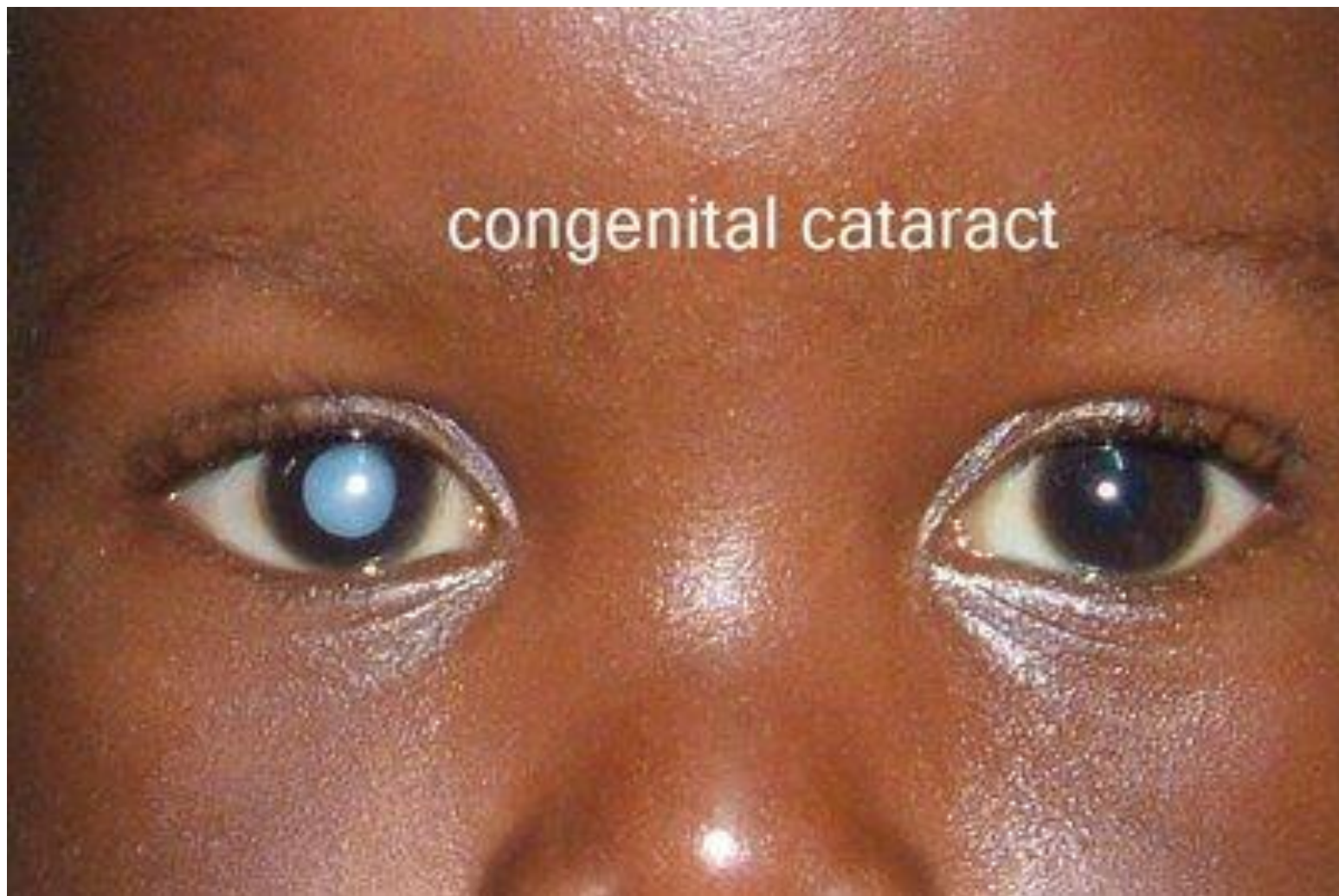
- In some cases, it can affect both eyes.

## **Causes of amblyopia include:**

- **Strabismus** - a disorder in which the two eyes don't line up in the same direction
- **Refractive error in an eye** - when one eye cannot focus as well as the other, because of a problem with its shape. This includes nearsightedness, farsightedness, and astigmatism.
- **Cataract** - a clouding in the lens of the eye

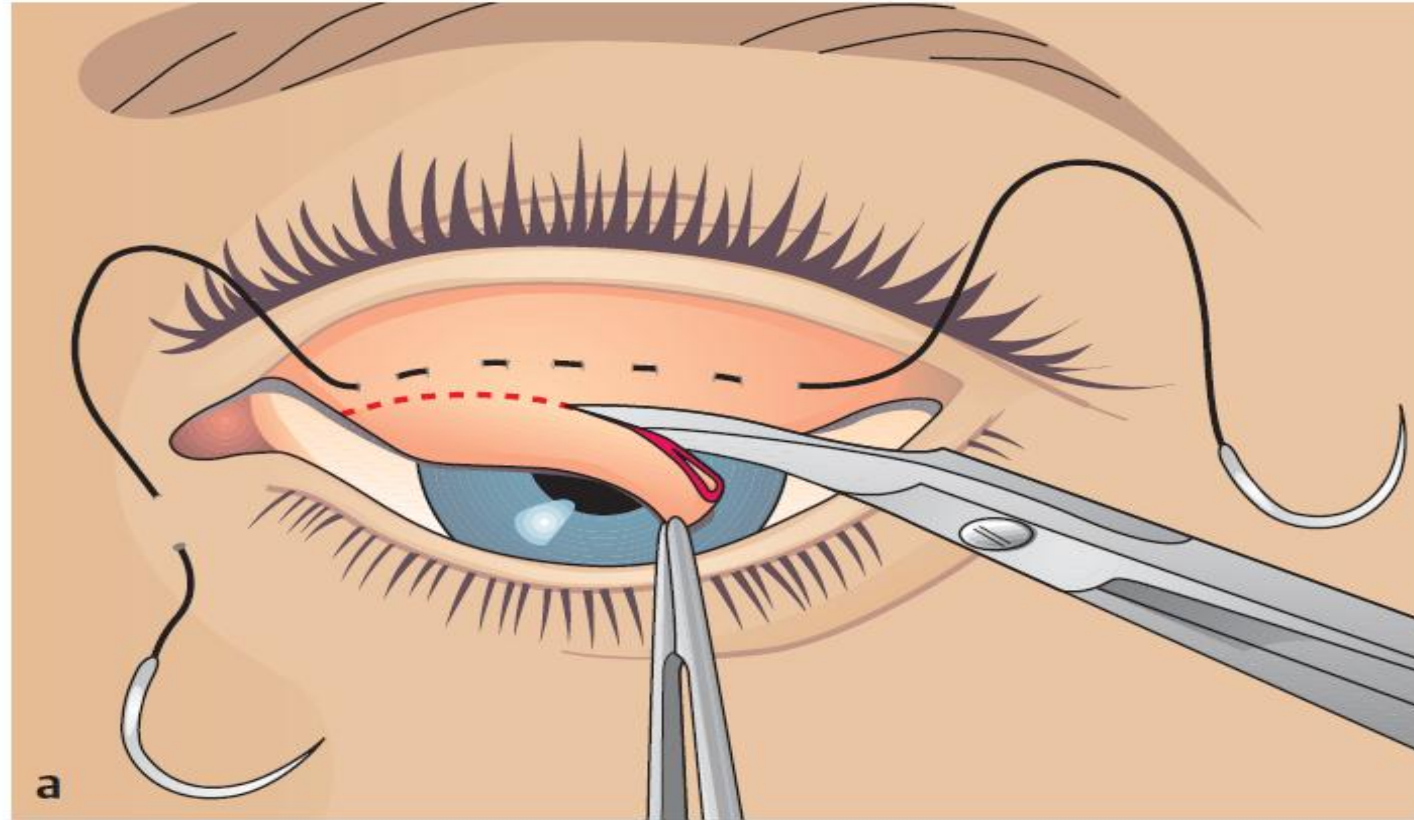


congenital cataract




# Methods of surgical retraction of the upper eyelid.

## Procedure one



**The Fasanella-Servat procedure**, indicated for correction of minimal ptosis, involves resection of a portion of the tarsus (2mm or less) to vertically shorten the eyelid.

# The Fasanella-Servat procedure



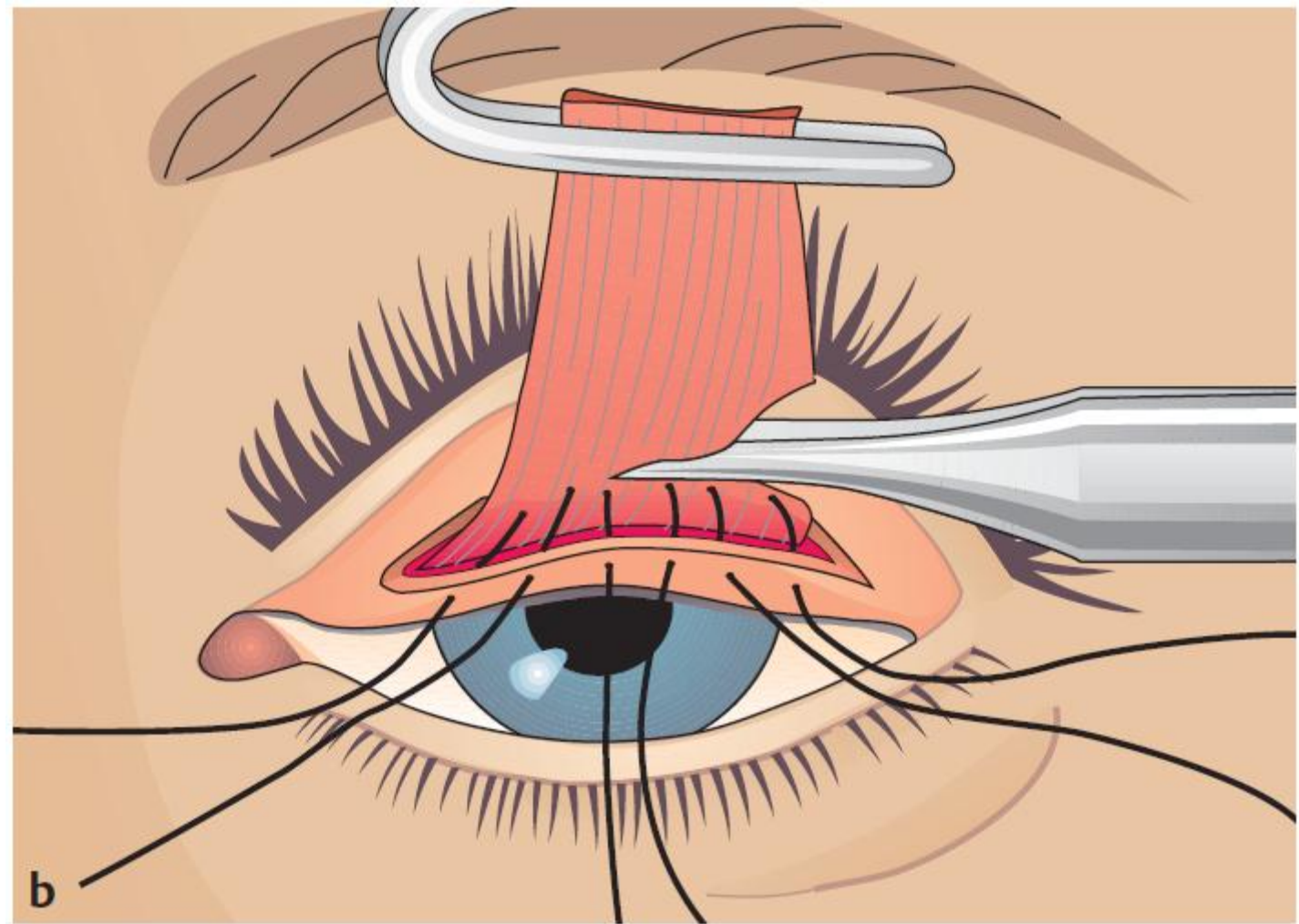
# The Fasanella-Servat procedure

**Fasanella Servat**



**Richard C. Allen MD, PhD, FACS**  
Department of Ophthalmology  
University of Iowa


## Procedure two



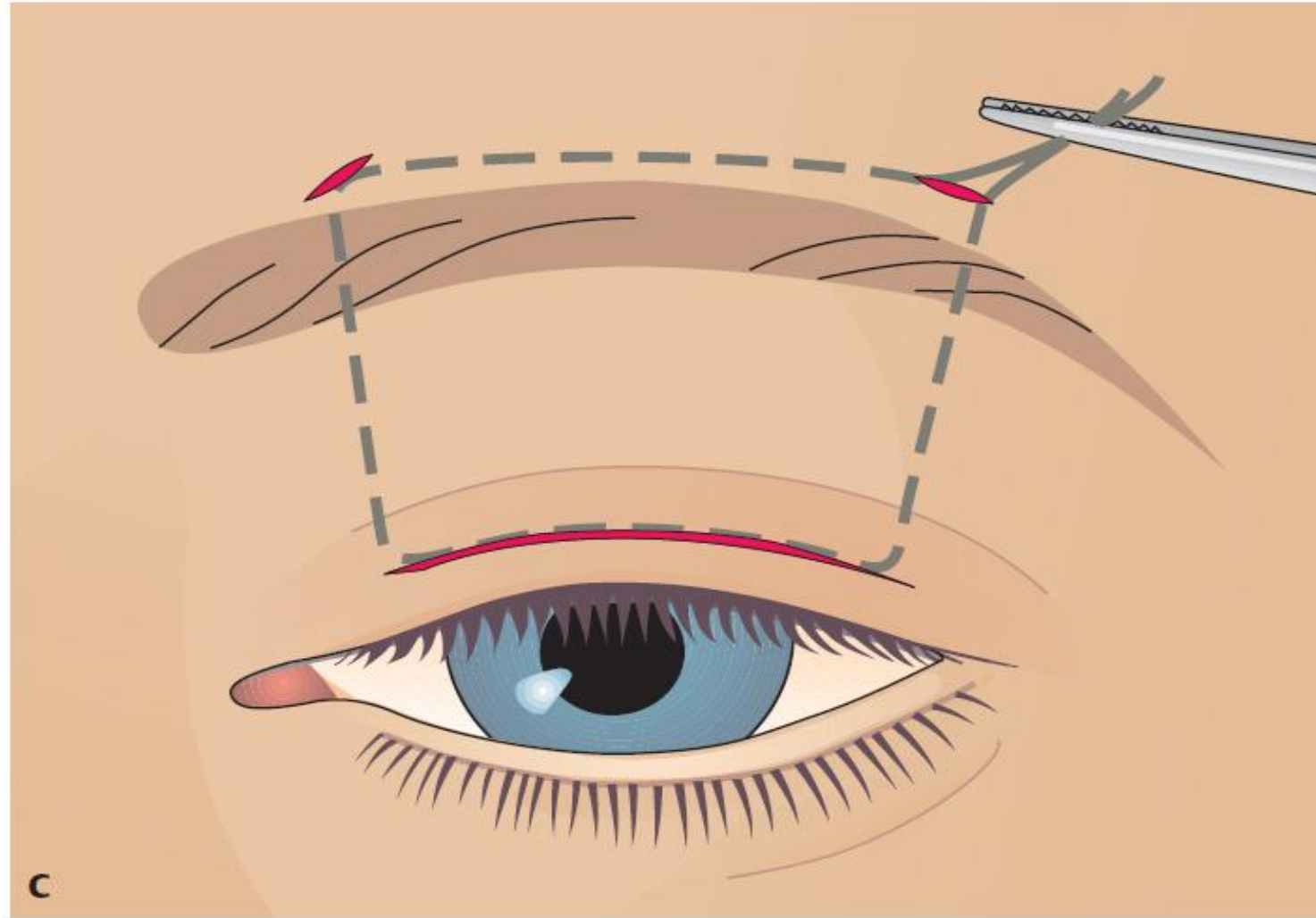
**levator resection :the amount of muscle removed in a levator resection depends on levator function (ranging from approximately 10mm with slight ptosis, up to 22mm with moderate ptosis).**



# levator resection



## Procedure three



**Where levator function is poor (less than 5 mm), the upper eyelid can be connected to tissue in the eyebrow region.**

## **Acquired ptosis:**

❖ **Involitional ptosis** is the most common ptosis encountered, often involves both upper lids of older patients, and may occur following cataract extraction. This is the most common form of acquired ptosis and is **caused by stretching of the levator aponeurosis or disinsertion of the levator muscle from its insertion onto the tarsus.**

- ❖ ***Paralytic ptosis in oculomotor palsy*** is usually **unilateral** with the drooping eyelid covering the whole eye. Often there will be other signs of palsy in the area supplied by the oculomotor nerve.
- ❖ In ***external oculomotor palsy***, only the extraocular muscles are affected (mydriasis will not be present), whereas in ***complete oculomotor palsy***, the inner ciliary muscle and the sphincter pupillae muscle are also affected (internal ophthalmoplegia with loss of accommodation, mydriasis, and complete loss of pupillary light reflexes).

- ❖ ***Myasthenia gravis*** (myogenic ptosis that is often **bilateral** and may be asymmetrical) is associated with abnormal fatigue of the striated extraocular muscles. Ptosis typically becomes more severe as the day goes on.
- ❖ **Sympathetic ptosis** occurs in Horner's palsy (ptosis, miosis, and enophthalmos).
- ❖ **Traumatic ptosis** can occur after injuries.
- ❖ **Mechanical ptosis** may be associated with lid tumors such as neurofibromas and may result from scars or foreign bodies.

**Note:** Rapidly opening and closing the eyelids provokes ptosis in myasthenia gravis and simplifies the diagnosis.

## **Treatment of acquired ptosis:**

- Depends on the cause.
- As palsies often resolve spontaneously, the patient should be observed before resorting to surgical intervention.
- Conservative treatment with special eyeglasses may be sufficient even in irreversible cases.
- Because of the risk of overcorrecting or undercorrecting the disorder, several operations may be necessary.
- **Repair of the levator aponeurosis** (tendon) if possible.
- In more severe cases, **the levator aponeurosis may be suspended from the frontalis muscle** if levator function is poor.



**To be continued.....**

